


Case Series



Endometriosis and Ovarian Cancer – A Case Series with Review of Literature

Bhagyalaxmi Nayak, Jagannath Mishra, Janmejaya Mohapatra, Jita Parija

Department of Gynaecologic Oncology, AH PG Institute of Cancer, Cuttack, Odisha, India

ABSTRACT

Aim: The aim of the study was to report our experience of endometriosis associated ovarian malignancy in four patients and present a review of the literature regarding this rare condition. **Background:** Although ovarian endometriosis is considered as a benign disease, it has the potential to become malignant mainly of endometrioid and clear cell subtypes of epithelial ovarian malignancy. There is a controversy about whether endometriosis-associated ovarian malignancy represents a different entity as compared to ovarian malignancy in the absence of endometriosis. **Case Report:** We report four cases of women who were diagnosed with endometriosis associated ovarian malignancy. Two cases were of the endometrioid subtype and two of clear cell subtype. Two of them were Stage IA1, and the other two were Stage IC1. More than 30 months after the diagnosis, three patients were alive and recurrence-free but one patient recurred after one and a half years of completion of chemotherapy. The present report critically discusses the main characteristics, management and prognosis of patients with ovarian malignancy associated with endometriosis. **Conclusion:** Endometriosis associated ovarian malignancy generally presents in early stage and has a favorable prognosis. **Clinical Significance:** Endometriosis is associated with an increased risk of developing epithelial ovarian cancer

Key words: Endometriosis, Ovarian Cancer, Clear cell Carcinoma

INTRODUCTION

Endometriosis is a common condition, present in ~10% of women in reproductive age group.^[1] It was first formally described in 1896 and is defined histologically by the presence of endometrial glands and stroma outside the endometrial cavity.^[2] It has been established that endometriosis is a precursor lesion for ovarian cancer. The previous studies have demonstrated an increased cancer incidence in women with endometriosis.^[3-5] Many retrospective studies have reported the association of endometriosis in women with ovarian cancer, particularly of the endometrioid carcinoma and clear cell types.^[6-8] This report describes four cases of endometriosis associated ovarian malignancy and critically discusses the main features of these patients.

Corresponding Author:

Dr. Bhagyalaxmi Nayak, Department of Gynaecology, Regional Cancer Centre, Cuttack, Odisha, India.
E-mail: blnayak2266@gmail.com

Received: 21-04-2021

Accepted: 29-04-2021

DOI: 10.15713/ins.jgog.11

CASE REPORT

Case 1

A 45-year-old, para 2, premenopausal woman presented with pain abdomen and bloating sensation to the Gynecological Oncology Unit, Acharya Harihar Post graduate Institute of Cancer, Cuttack, Odisha, India. There was no family history of any malignancy. The clinical examination of the abdomen revealed an ill-defined supra-pubic mass extending upto umbilicus.

Abdominal ultrasound and contrast enhanced computed tomography (CECT) scan showed a mass in the right ovary measuring 84 mm × 76 mm × 64 mm in the absence of ascites. Serum cancer antigen 125 (CA-125) concentration was 175 U/mL (normal range <35 U/mL). After the positive frozen section pathological examination in the ovarian mass, patient underwent a total abdominal hysterectomy, bilateral salpingo-oophorectomy, bilateral pelvic and para-aortic lymphadenectomy, omentectomy, appendectomy, and peritoneal biopsies. Pathological findings revealed an invasive endometrioid carcinoma, Grade 2 without involvement of the surface of the right ovary (Stage IA1 and Grade 2) in association with endometriosis. Peritoneal cytological washing and biopsies, omentum as well as lymph nodes were negative for malignant cells. Patient was planned for routine follow-

up. Up to the last follow-up visit (November 2020), the patient was recurrence-free.

Case 2

A 35-year-old, para 2, obese, premenopausal woman was referred with complaints of lower abdominal pain with H/O of dysmenorrhea during the last month. Examination using ultrasonography showed a mass in the lower abdomen measuring 13 cm × 10 cm. Magnetic resonance imaging (MRI) identified a cystic lesion with solid components of the left ovary, fluid in Douglas space. CA-125 concentration was 90 U/mL (normal range <35 U/mL). The patient underwent a total abdominal hysterectomy, bilateral salpingo-oophorectomy, bilateral pelvic and para-aortic lymphadenectomy, omentectomy, and peritoneal biopsies. The fluid in Douglas space and the peritoneal biopsies, lymph nodes and omentum were negative for malignancy. Pathological findings revealed a well-differentiated endometrioid tumor of the left ovary without invasion of the surface of the ovary and features of endometriosis (Stage IA1 and Grade 1). The patient did not receive adjuvant chemotherapy and we suggested a regular follow-up. Up to the last follow-up visit (December 2020), the patient was recurrence-free.

Case 3

A 38-year-old, para 2, premenopausal woman was referred with lower abdominal pain and bloating during the past 6 months. Her medical history involved hypothyroidism, hypertension. CA-125 concentration was 185 U/mL (normal range <35 U/mL). CECT and ultrasound examination showed a mass in the right ovary (10 cm × 12 cm) and minimal free fluid in the pouch of Douglas. The patient underwent a total abdominal hysterectomy, bilateral salpingo-oophorectomy, bilateral pelvic and para-aortic lymphadenectomy, and omentectomy. Pathological findings revealed a clear cell carcinoma in the right ovary with surface involvement (Grade 3 and Stage IC1) Figure 1 in the vicinity of endometriosis and peritoneal cytological washing and biopsies, omentum as well as lymph nodes were negative for malignant cells. The patient received adjuvant chemotherapy with paclitaxel (175 mg/m²) and carboplatin AUC 6 for six cycles. Up to the last follow-up visit (November 2020), the patient was alive and recurrence-free.

Case 4

A 27 years, married for two years, presented with amenorrhea and inability to conceive. There was definite h/o progressive dysmenorrhea. Per abdomen, she had a mass of 24 weeks, restricted mobility. CT scan revealed heterogeneous mass in both ovaries with minimal ascites. CA125 was 546 U/ml. Other markers for germ cell tumour were normal. She was counselled and taken up for fertility-sparing surgery. The frozen section of the larger right ovarian tumour was clear cell carcinoma and the left smaller ovarian tumour was endometriosis. Complete surgical staging followed by 6 cycles of Chemotherapy with Paclitaxel carboplatin was given. Contrary to the belief that these

Table 1: Characteristics of the three endometriosis associated ovarian malignant tumors

Age (years)	CA 125 (IU/ml)	Histologic Sub type	Grade	Stage	Adjuvant chemo	Recurrence free survival
45	175	Endometrioid	1	IA1	No	33 months
35	90	Endometrioid	2	IA1	No	36 months
38	185	clear cell	3	IC1	Yes	29 months

CA: Cancer antigen

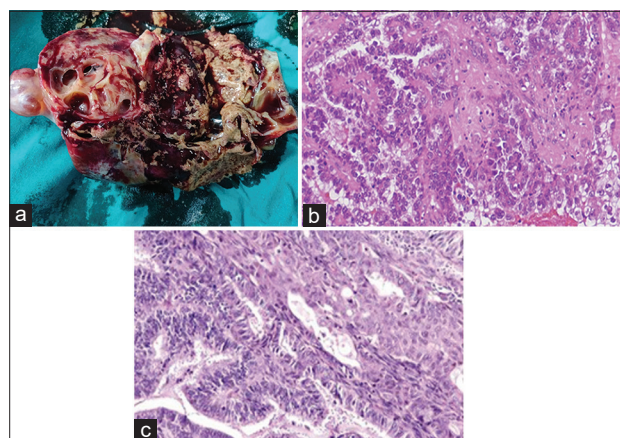


Figure 1: (a) Cut section of a ovarian mass showing chocolate material with solid components (b) clear cell carcinoma ovary associated with endometriosis (c) Endometrioid adenocarcinoma in the vicinity of endometriosis

tumours associated with endometriosis have a good prognosis, she developed the recurrent disease in the paraaortic area just after one and a half years of completion of six cycles of Data of the four reported cases are summarized in Table 1.

DISCUSSION AND REVIEW OF LITERATURE

Endometriosis is associated with an increased risk of developing epithelial ovarian malignancy primarily a subclass of Type I ovarian neoplasms including endometrioid and clear-cell histology. Despite the evidence to support the malignant transformation of endometriosis, the risk of developing an ovarian carcinoma from endometriosis is relatively low with frequencies cited between 0.3% and 0.8%^[9,10] However, with endometriosis affecting approximately 10–15% of all premenopausal women and from 30% to 50% of women with a diagnosis of infertility, it is important to understand the clinical characteristics of these subset of patients to provide earlier diagnosis and develop prevention strategies for these women. The criteria for endometriosis-associated ovarian malignancy that was initially suggested by Sampson and Scott continued to be used. These include (1) the coexistence of carcinoma and endometriosis in the same ovary; (2) presence of tissue resembling endometrial stroma surrounding characteristic epithelial glands; (3) exclusion of a metastatic tumor to the ovary; and (4) presence of benign

endometriosis histologically close to the tumor.^[11,12] These tumors are thought to arise from mutations in different genes and signaling pathways such as PTEN, ARID1A, KRAS, and CTNNB1. These mutations cause histologic changes known as intermediary stage (atypical endometriosis) and finally to the malignant form. On the basis of these mutations, it is proposed that endometriotic cells accumulate these somatic mutations, leading to histologic atypia, and eventually transformation to ovarian cancer. The timeline and precise genomic steps for this process remain to be determined. Many studies have shown that patients diagnosed with endometriosis associated ovarian malignancies are younger, more seen in premenopausal women and have a lower grade tumor than those with other epithelial ovarian malignancies like our report.^[13] Davis *et al.* compared clinical outcomes of the most common type of ovarian tumor, papillary serous, and outcomes of endometriosis associated ovarian malignancies.^[14] The results showed that compared to papillary serous subtypes, they were associated with an earlier stage (I/II), lower grade, and better outcome also. However, it is unclear whether the increased survival is related to the younger age and/or the earlier diagnosis reported in women with endometriosis. Komiyama *et al.* have documented a better prognosis also adjusting for ovarian cancer stage while other authors failed to demonstrate any difference when controlling for both stage and age. In another recent meta-analysis on 20 case-control and 15 cohort studies that included 444,255 patients reported that there were no differences in progression free survival (HR, 1.023), but a slightly better overall survival (HR, 0.778) in endometriosis associated ovarian malignancies as compared to other epithelial ovarian malignancies.^[15] Ultrasonography is commonly used to identify the nature of ovarian tumors to know risk of malignancy index. In a study by Kadan *et al.* which included 73 patients with clear and mixed endometrioid-clear cell tumors that were associated with endometriosis, most tumors were found to be unilateral and were cystic without the presence of ascites. When compared with benign endometriomas, endometriosis associated ovarian malignant tumors were larger (14 cm vs. 7.5 cm), more often multilocular (45.7% vs. 12.2%), and contained solid components (77.1% vs. 14.5%).^[16] Taniguchi *et al.* reported the appearance of mural nodules within the endometriomas by ultrasonography in all cases of endometriosis associated ovarian malignant tumors. He noticed rather than size but rapid growth of the endometrioma (doubled in size 6 months before the diagnosis of malignant transformation) in 30/33 of their patients and should be used as an indicator for malignant transformation.^[17] Serum CA-125 levels are a poor screening modality for endometriosis associated ovarian malignant tumors. CA-125 levels found in endometriosis associated ovarian malignant tumors is lower as compared to patients with other epithelial malignant tumors (mean: 122.9 vs. 1377.5 U/mL, $P < 0.001$), and patients associated with endometriosis were more likely to display normal CA-125 level ($P < 0.001$).^[13]

CONCLUSION

Endometriosis associated ovarian malignant tumors are more likely to be associated with endometrioid and clear cell

carcinoma. Based on molecular studies, CTNNB1 and ARID1A mutations were particularly related to these two histological types. Caution should be paid in cases with rapid growth of endometrioma and with solid components. Patients who are nulliparous, who are diagnosed at older age and with long-term endometriosis should be paid special attention to the possibility of malignant transformation. More awareness should be focussed on unilateral, larger, and multilocular cyst with solid components that showed rapid growth.

REFERENCES

- Olive DL, Schwartz LB. Endometriosis. *N Engl J Med* 1993;328:1759-69.
- Cullen TS. Adenoma-myoma uteri diffusum benignum. *Johns Hopkins Hosp Bull* 1896;6:133-7.
- Brinton LA, Gridley G, Persson I, Baron J, Bergqvist A. Cancer risk after a hospital discharge diagnosis of endometriosis. *Am J Obstet Gynecol* 1997;176:572-9.
- Ness RB, Cramer DW, Goodman MT, Kjaer SK, Mallin K, Mosgaard BJ, *et al.* Infertility, fertility drugs, and ovarian cancer: A pooled analysis of case-control studies. *Am J Epidemiol* 2002;155:217-24.
- Brinton LA, Lamb EJ, Moghissi KS, Scoccia B, Althuis MD, Mabie JE, *et al.* Ovarian cancer risk associated with varying causes of infertility. *Fertil Steril* 2004;82:405-14.
- Vercellini P, Parazzini F, Bolis G, Carinelli S, Dindelli M, Vendola N, *et al.* Endometriosis and ovarian cancer. *Am J Obstet Gynecol* 1993;169:181-2.
- Chew S, Tham KF, Ratnam SS. A series of ovarian clear cell and endometrioid carcinoma and their association with endometriosis. *Singapore Med J* 1997;38:289-91.
- Borgfeldt C, Andolf E. Cancer risk after hospital discharge diagnosis of benign ovarian cysts and endometriosis. *Acta Obstet Gynecol Scand* 2004;83:395-400.
- Moll U, Chumas J, Chalas E, Mann W. Ovarian carcinoma arising in atypical endometriosis. *Obstet Gynecol* 1990;75 3 pt 2:537-9.
- Heaps J, Nieberg R, Berek J. Malignant neoplasms arising in endometriosis. *Obstet Gynecol* 1990;75:1023-8.
- Sampson JA. Metastatic or embolic endometriosis, due to the menstrual dissemination of endometrial tissue into the venous circulation. *Am J Pathol* 1927;3:93-110; 143.
- Scott RB. Malignant changes in endometriosis. *Obstet Gynecol* 1953;2:283-9.
- Wang S, Qiu L, Lang JH, Shen K, Yang JX, Huang HF, *et al.* Clinical analysis of ovarian epithelial carcinoma with coexisting pelvic endometriosis. *Am J Obstet Gynecol* 2013;208:e411-5.
- Davis M, Rauh-Hain JA, Andrade C, Boruta DM 2nd, Schorge JO, Horowitz NS, *et al.* Comparison of clinical outcomes of patients with clear cell and endometrioid ovarian cancer associated with endometriosis to papillary serous carcinoma of the ovary. *Gynecol Oncol* 2014;132:760-6.
- Kim HS, Kim TH, Chung HH, Song YS. Risk and prognosis of ovarian cancer in women with endometriosis: A meta-analysis. *Br J Cancer* 2014;110:1878-90.
- Kadan Y, Fiascone S, McCourt C, Raker C, Granai CO, Steinhoff M, *et al.* Predictive factors for the presence of malignant transformation of pelvic endometriosis. *Eur J Obstet Gynecol*

Reprod Biol 2015;185:23-7.

17. Taniguchi F, Harada T, Kobayashi H, Hayashi K, Momoeda M, Terakawa N. Clinical characteristics of patients in Japan with ovarian cancer presumably arising from ovarian endometrioma. *Gynecol Obstet Invest* 2014;77:104-10.

How to cite this article: Nayak B, Mishra J, Mohapatra J, Parija J. Endometriosis and Ovarian Cancer – A Case Series with Review of Literature. *J Glob Obstet Gynecol* 2021;1(1):48-51.

Source of support: Nil, **Conflict of Interest:** Nil.

This work is licensed under a Creative Commons Attribution 4.0 International License. The images or other third party material in this article are included in the article's Creative Commons license, unless indicated otherwise in the credit line; if the material is not included under the Creative Commons license, users will need to obtain permission from the license holder to reproduce the material. To view a copy of this license, visit <http://creativecommons.org/licenses/by/4.0/> © Nayak B. 2021